

Case of the month – February 2010 - 1

A 26-year-old young woman is presented to the orthopaedic department. She reports an operation of the right elbow with transfer of the ulnar nerve 4 years ago, but pain remained moderate to intense, increasing during the night. A medication with nonsteroidal anti-inflammatory drugs (NSAID) is used with good results.

Case of the month – 02/10 - 2

- At time of presentation the X-ray shows a small rounded to oval area of osteolysis, surrounded by a regular halo of bone sclerosis in the region of the ulnar suclus (Fig. 1)
- What is your diagnosis?

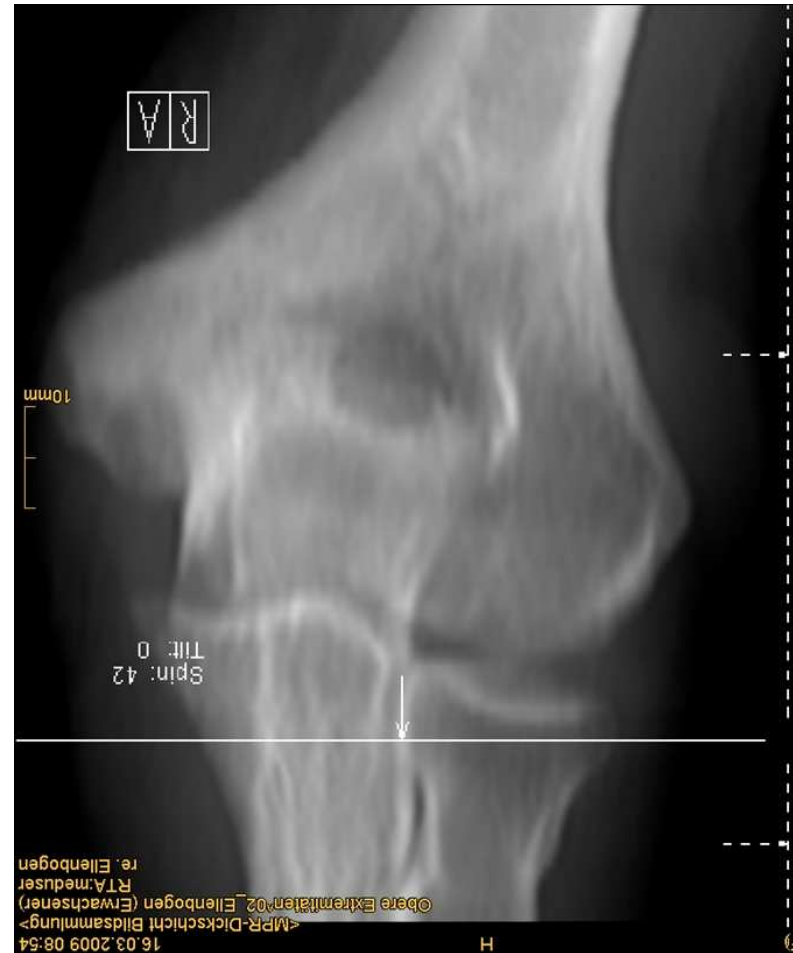

Fig. 1

Case of the month – 02/10 - 3

- Comment: Several differential diagnoses have to be considered as a possible reason for the imaging presentation: Brodie's abscess, sclerosing Osteoperiostitis, Fatigue-Fracture Osteoidosteom and Osteoblastoma.

Case of the month – 02/10 - 4

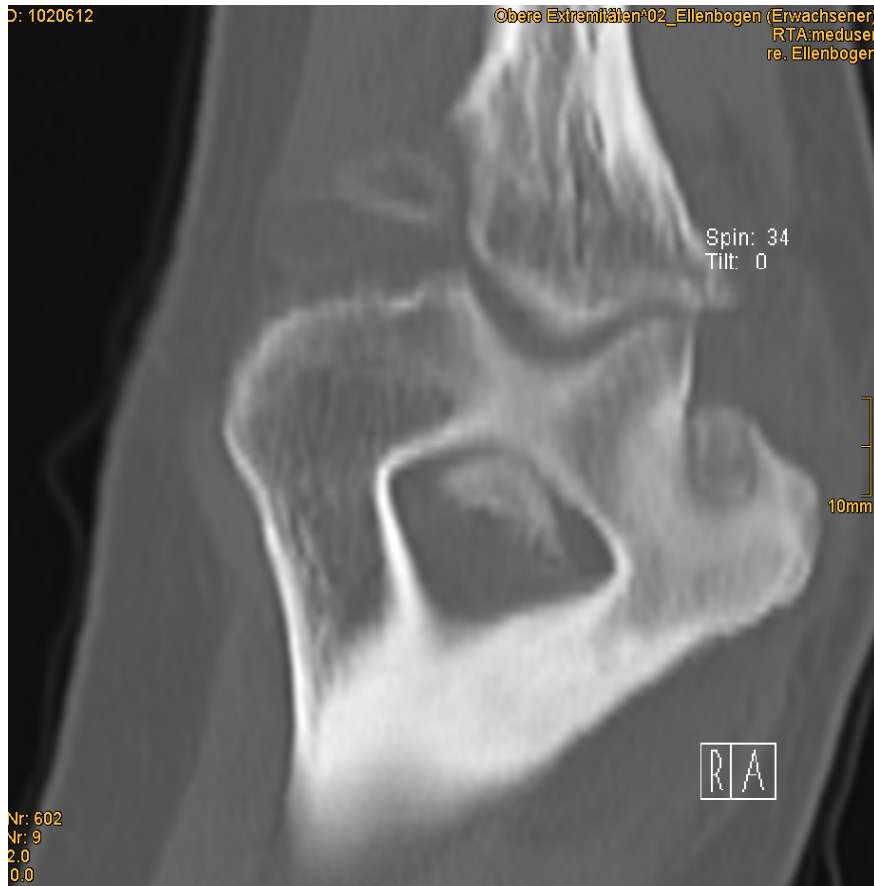- In view of this information what might be a good diagnostic procedure at this time?

- Hemogram (including complete- (CBC) and white-blood count (WBC), differential WBC, platelets, polymorphonuclear leucocytes, erythrocyte sedimentation rate (ESR)
- CT-Scan
- Isotope bone scan
- Arteriography
- MRI

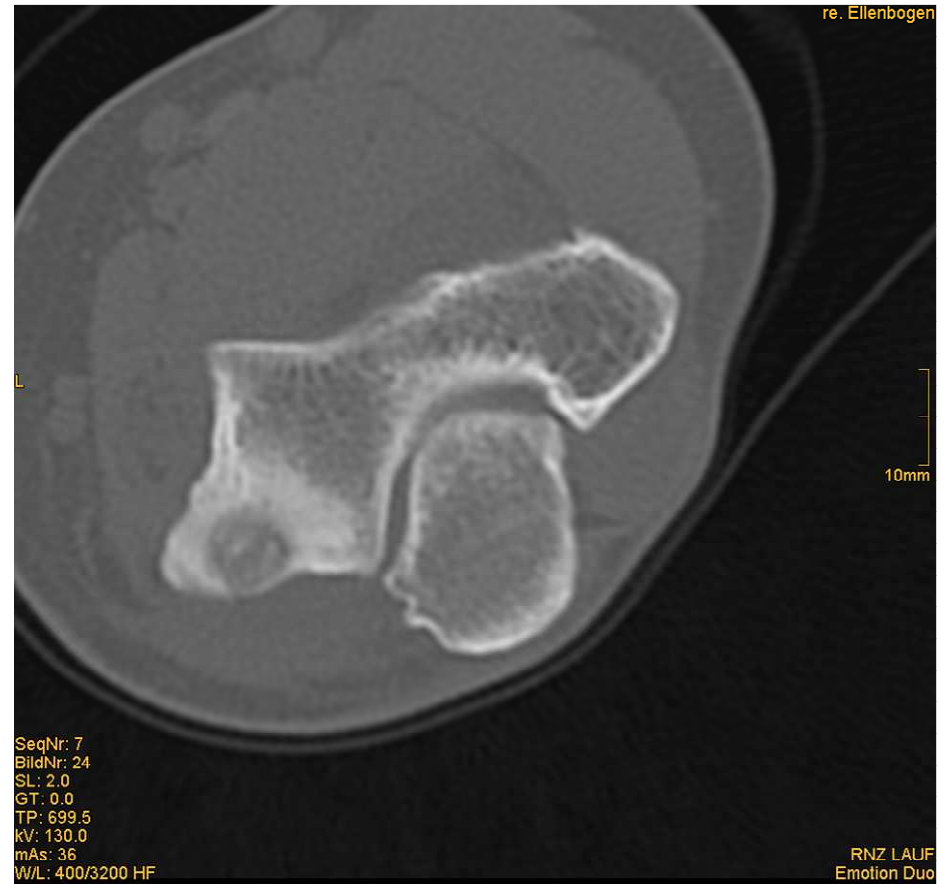
Case of the month – 02/10 - 5

- Comment: Blood tests are necessary to exclude differential diagnoses such as Brodie's abscess. The round to oval area of osteolysis is best shown by CT-Scan (Figs. 2 and 3). An Arteriography with subtraction of the bone density may demonstrate a nidus which might be highly vascular, but is not necessary in general. The MRI is sensitive to show possible inflammatory reaction of the surrounding tissues, which may confuse the diagnosis.

Case of the month – 02/10 - 6



• Fig. 2



• Fig. 3

Case of the month – 02/10 - 7

- The diagnosis after CT-Scan is Osteoid osteoma.
- At this time, what would be the treatment of choice?

- Medical treatment (NSAID)
- Surgery
- Percutaneous CT-guided core drill
- Coagulation of the nidus (radiofrequency)

Case of the month – 02/10 - 8

- Comment: Surgery is usually indicated, with the exception of very rare lesions which are scarcely painful, or of patients who elect to have a prolonged medical treatment. Recently, percutaneous CT-guided core-drill removal, or coagulation of the nidus with radiofrequency, laser or ethanol have been introduced with promising results, but offer less constant cure rates as compared to the surgical technique.

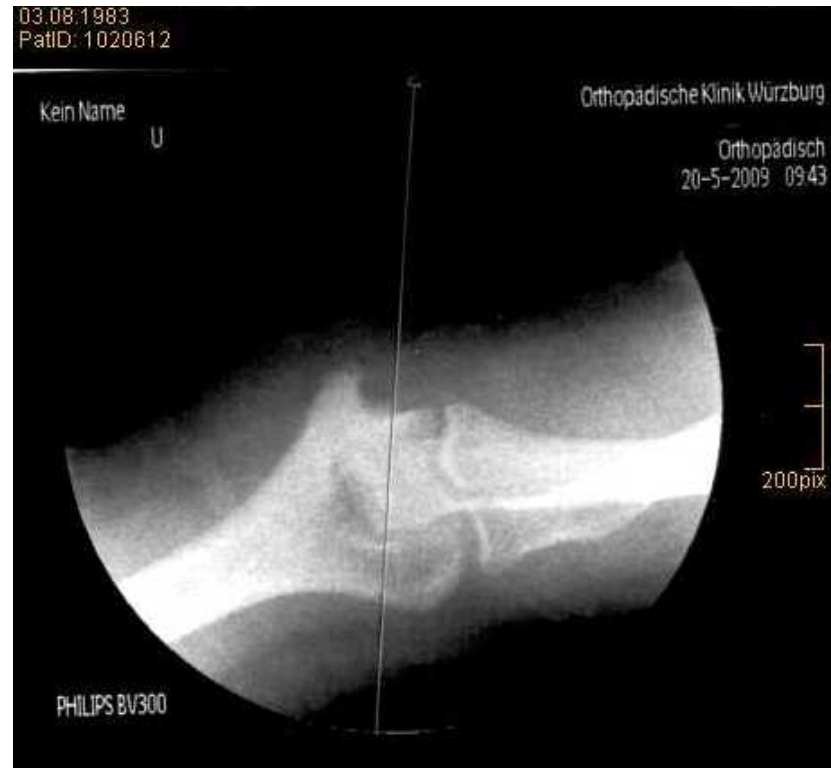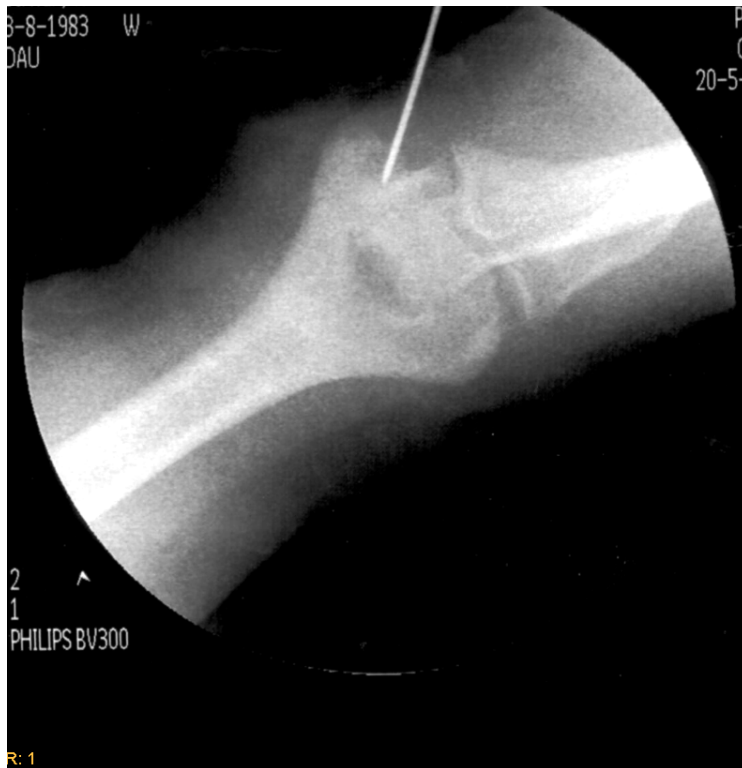Case of the month – 02/10 - 9

- Which kinds of surgery should be taken into consideration?
 - directly and widely expose the surface of the bone
 - removing all overlying reactive soft tissue
 - complete removal of the nidus
 - bone grafting
 - internal fixation

Case of the month – 02/10 - 10

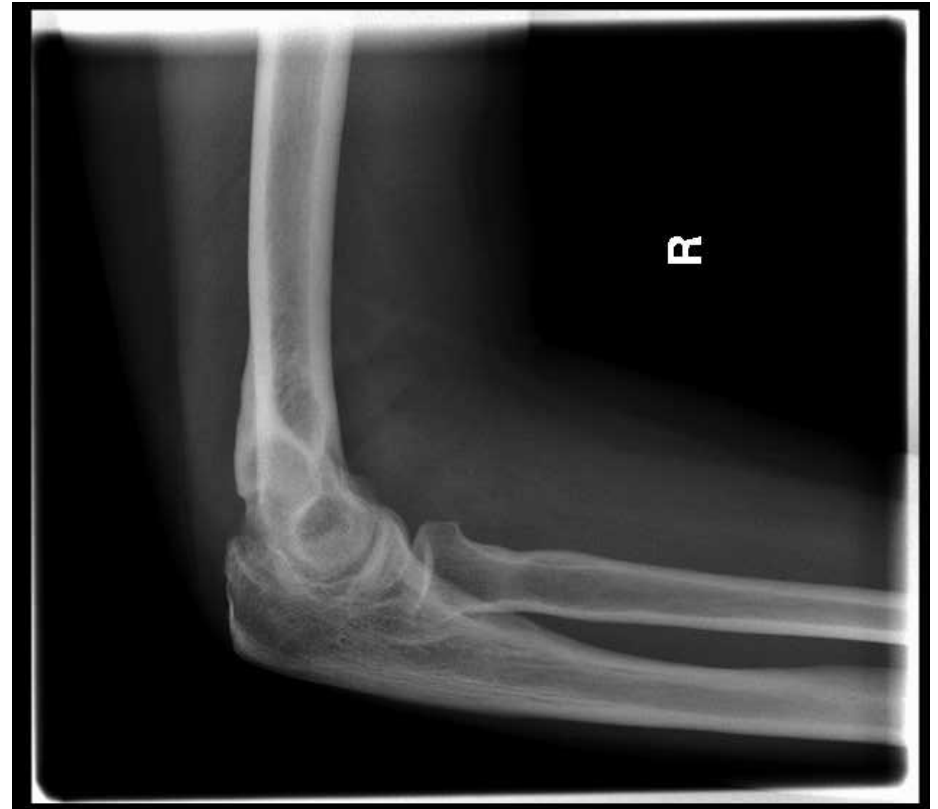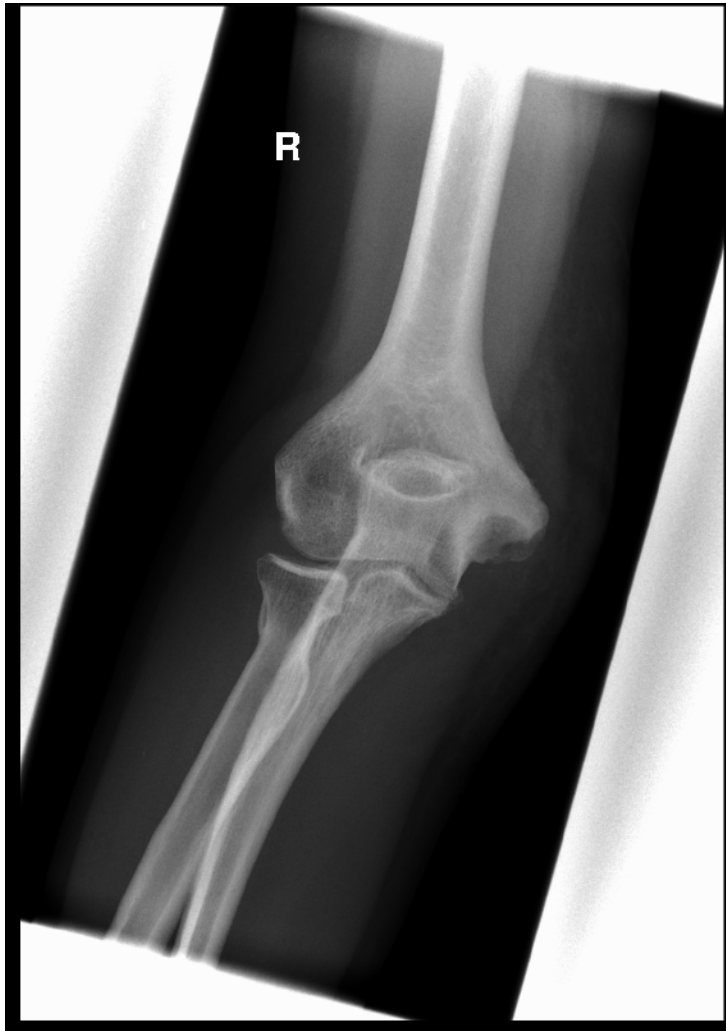- Comment: The surface of the bone should be widely exposed in the area of the Osteoid osteoma, removing all overlying reactive soft tissues, joints should be opened. The reactive sclerotic bone, covering the nidus should be removed. The nidus appears as a reddish spot and should be completely removed (Fig. 4), the bony walls can be smoothed by curette. Usually, there is no need for bone grafting, internal fixation or postoperative external protection (Fig.5).

Case of the month – 02/10 - 11



- Fig. 4

Case of the month – 02/10 - 12



- Fig. 5

Case of the month – 02/10 - 13

- Osteoid osteoma is a benign tumor, painful and small, consisting of woven bone and osteoid, surrounded by a halo of reactive bone formation. The tumor is relatively frequent (4% of all bone tumors). There is a predilection for the male sex and it is typical for late childhood, adolescence and young adult age. Osteoid osteoma prevalently occurs in the appendicular skeleton. In the long bones, the localization may be diaphyseal, metaphyseal or rarely epiphyseal. There is a high preference for the proximal femur. Pain is the characteristic symptom, increasing during the night, relieved by non steroid anti-inflammatory drugs. The imaging presentation is typical with a small rounded area of osteolysis (diameter <2cm), surrounded by a halo of bone sclerosis.

Case of the month – 02/10

Author:

Martin Luedemann, MD

Department of Orthopaedic Surgery

Brettreichstr. 11

D-97074 Würzburg

Germany

Tel.: +49 931 803-1102 /-1101

Fax: +49 931 803-1109

l-orthopaedie.klh@mail.uni-wuerzburg.de